



PICTURE BOOK OF INFECTIOUS POULTRY DISEASES



MARCH 2010

ECTAD SOUTHERN AFRICA



Contents

| | |
|-----------------------------------|-------|
| Acknowledgements | ii |
| Introduction | 1 |
| Anatomy of chicken | 2 |
| Viral disease | 3-4 |
| 1. Avian Influenza | |
| 2. Fowl pox | 5 |
| 3. Infectious Bronchitis | 6-7 |
| 4. Gumboro | 8 |
| 5. Marek`s Disease | 9-11 |
| 6. New castle Disease | 12-13 |
| Bacterial Disease | 14 |
| 1. Fowl Cholera | 14 |
| 2. Infectious Corzy | 15 |
| Parasitic Disease | 16 |
| 1. Coccidiosis (Eimeria necatrix) | 17 |
| 1. Coccidiosis (Eimeria tenella) | 17 |
| 2. Heterakis | 18 |
| 3. Ascarades | 18 |

Produced by FAO ECTAD Southern Africa for training purposes. Reproduction and dissemination of material in this information product for educational or other non-commercial purposes are authorized without any prior written permission, provided the source is fully acknowledged.

Acknowledgements

ECTAD Southern Africa acknowledges the contribution of the following;

- Dr. Jenica Lee, DVM from Ceva, Malaysia
- Dr. Vincent Turblin DVM from Ceva Asia-Pacific
- Paul Selleck, Research Scientist from Australian Animal Health Laboratory.
- FAO ECTAD, Regional office for Asia and the Pacific

These partners have made available their pictures to the collection as presented in this training booklet.

The financial contribution of USAID, SIDA and CIDA to the production and printing costs of the booklet are gratefully acknowledged.

Design: C.K. Marketing, Gaborone, Botswana

Printed by: Printing and Publishing Company Botswana PPCB

©FAO 2010

Introduction :

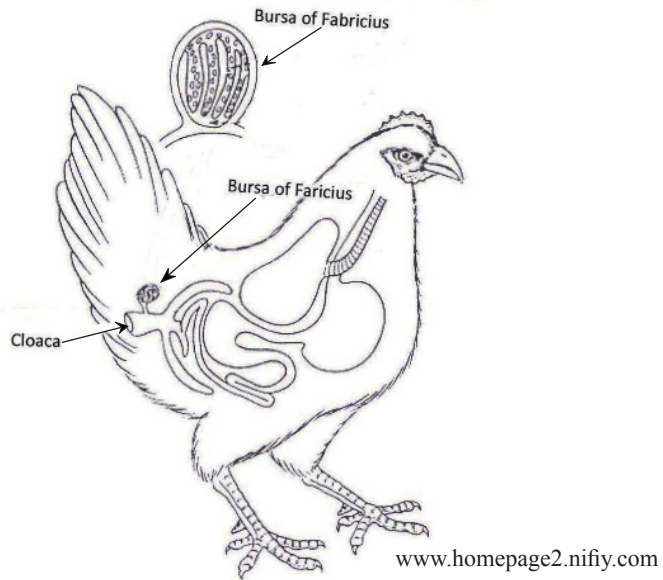
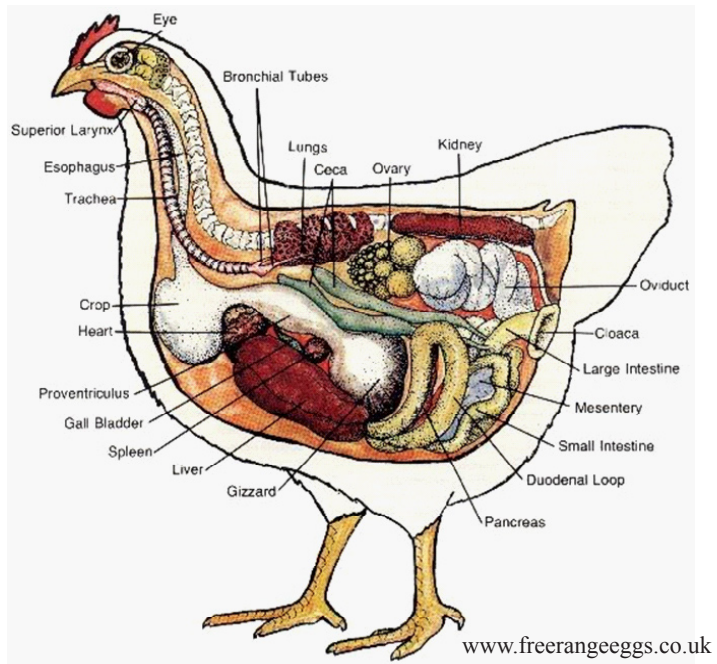
This “Picture book on infectious poultry diseases” has been compiled as a training tool for extension personnel involved in avian disease awareness work. The specific objective of collecting pictures of different but clinically similar diseases was to support training of extensionists and poultry owners in detecting Highly Pathogenic Avian Influenza (HPAI) should it occur in the currently disease free southern African region.

The booklet lists all diseases that could be mistaken on clinical appearance for Highly Pathogenic Avian Influenza.

We promote the wide usage of this booklet and encourage users to give us feedback on its usefulness and provide us with suggestions for improvement.

The ECTAD Southern Africa team
March 2010

Anatomy of Chicken



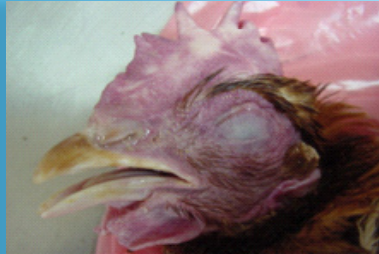VIRAL DISEASE

1. Avian Influenza (*Orthomyxoviridae*)

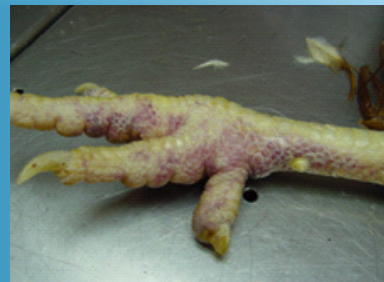Purple discoloration of wattles and combs with swelling caused by abnormal accumulation of fluid.



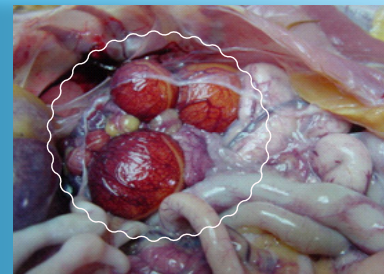
Swollen head, accumulation of liquid in eyelids and comb



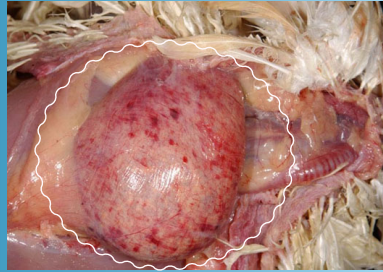
Pinpoint bleeding under the skin (mostly seen on feet and shanks)



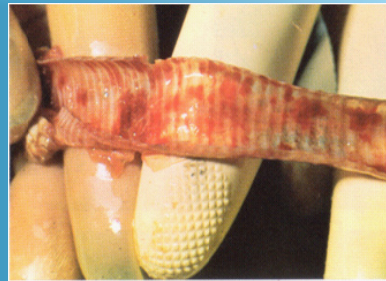
Bleeding into the ovaries



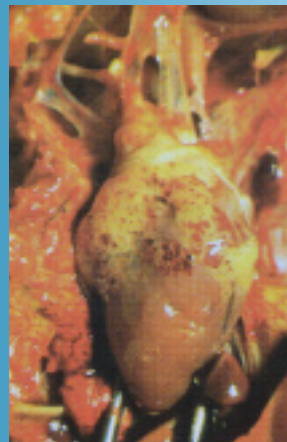Bleeding into the gizzard.



Bleeding in the mucosa of trachea

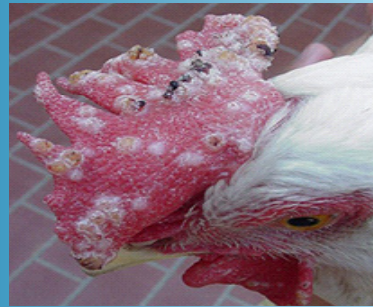

Bleeding in the muscle and in the fat around the heart

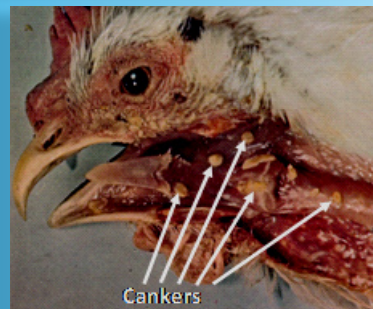

2. Fowl Pox (*Poxviridae*)

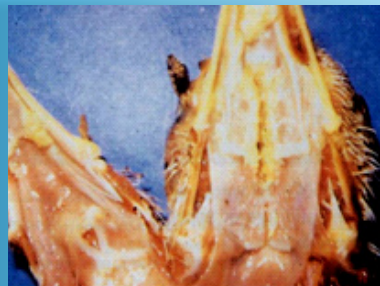Dry form: wart-like nodules on the skin (combs, face and wattles)



Wet form : Cankers are imbedded in the membranes of the mouth, larynx and trachea.



Wet form: Brown nodular lesions in the mucosa membrane of larynx; when removed, an eroded area is left.



3. Infectious Bronchitis (*Coronavirus*)

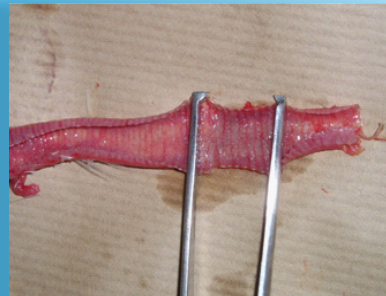Respiratory signs: difficulty in breathing (open beak) and swelling of face.



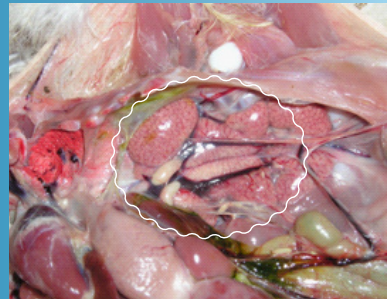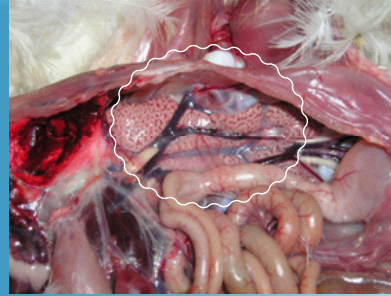
Marked drop in egg production and increased number of poor quality eggs-soft shelled with watery content.



Mild to moderate irritation of respiratory tract with swelling of trachea.

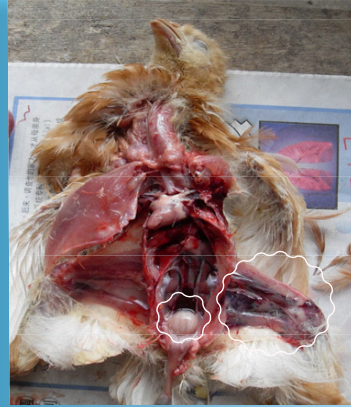

Swollen and pale kidneys with distended urinary tubes

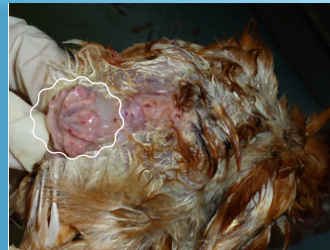

4. Gumboro (*Birnavirus*)

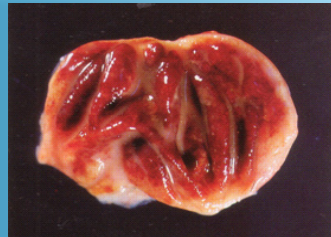
Bleeding into skeletal muscles,
enlarged bursa of Fabricius.



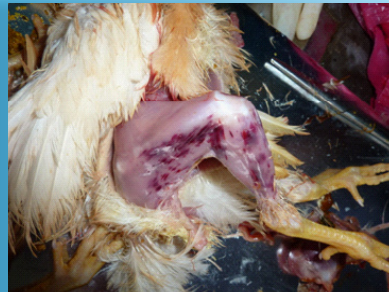Swollen bursa of Fabricius
(may be enlarged, of normal
size or reduced in size, de-
pending on the stage)



Bleeding and swollen bursa of
Fabricius.



Bleeding into skeletal muscle
of leg.



5. Marek's Disease (*Herpesvirus*)

Neurological form
(progressive paralysis):

Paralysis (loss of muscle function) of wings, characteristic dropping of limb.



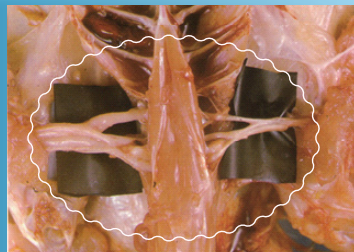
Twisted neck (torticollis)



Lameness.

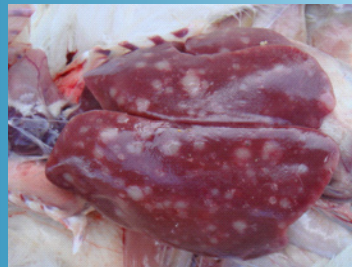
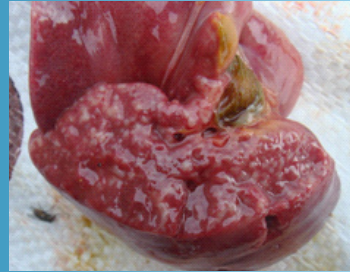
Brachial plexus (nerve) is two or three times the normal thickness, swelling caused by fluid (oedema).




Visceral form:

Enlarged liver with diffuse grayish nodules formed by abnormal growth of tissue.



Enlarged spleen with diffuse grayish discolorations



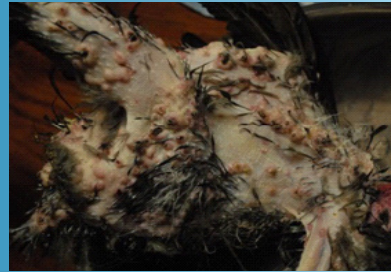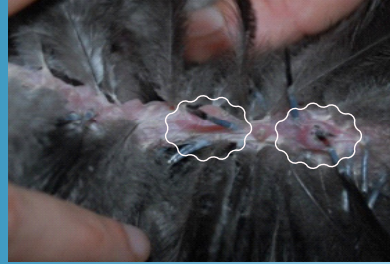
Enlarged

Normal size

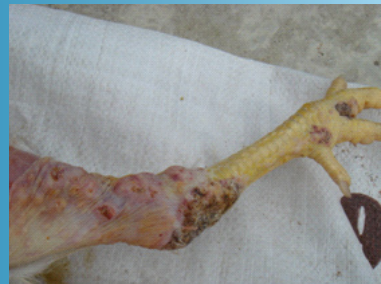

Cutaneous form:

Solid nodular lesions formed by abnormal growth of skin around the feather follicles.



Nodular skin lesions
(abnormal growth
of skin)



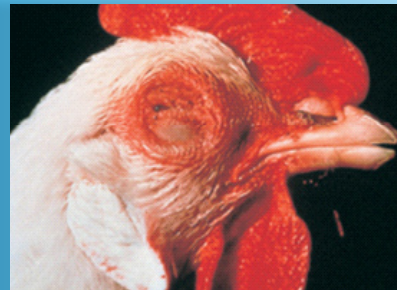6. Newcastle Disease

(Paramyxoviridae)

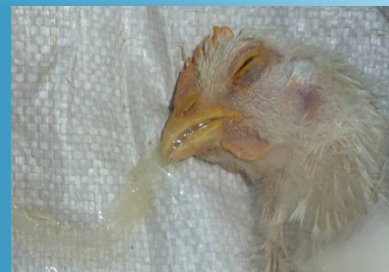Weakness (no lameness and no stiff neck).



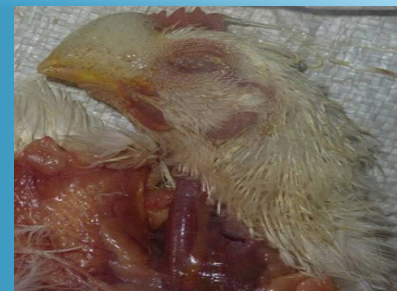Pink eye and swollen eyelids with abnormal accumulation of liquid



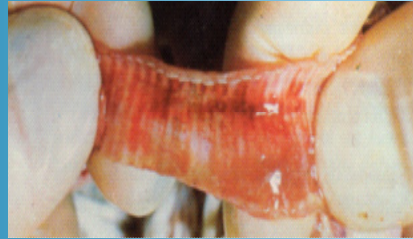
Foamy discharge from respiratory tract



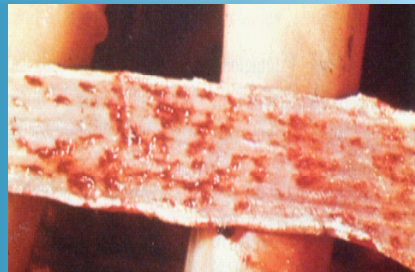Foamy nasal discharge, accumulation of liquid in the lungs.



Acute form: bleeding into the mucosa of the trachea.



Bleeding throughout the intestine.

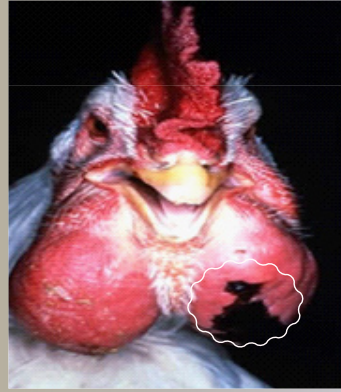


BACTERIAL DISEASE

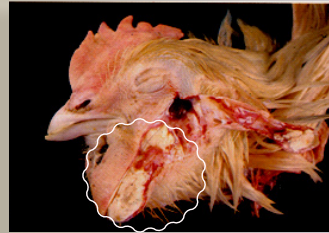
1. Fowl Cholera

(Pasteurella)

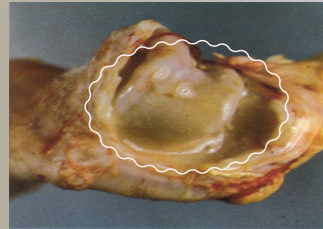
Blue coloration of wattles,
swollen wattles and face.



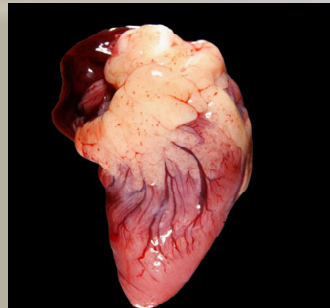
Yellow-brown pus
accumulated in a swollen
wattle



Pus (whitish to yellow)
accumulated in a hock joint.

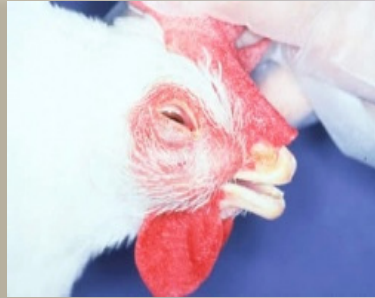

Pinpoint bleeding in the
muscles of heart

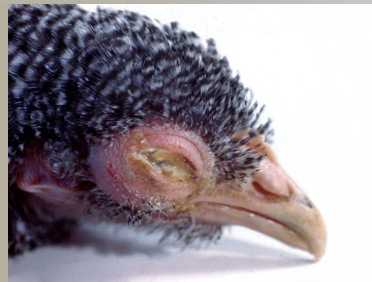

2. Infectious Coryza (*Haemophilus*)

Watery swollen eyes and face,
purulent nasal exudates.



Eyelids stick together by
mucous and exudates.

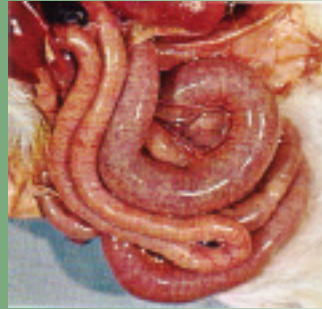

PARASITIC DISEASE

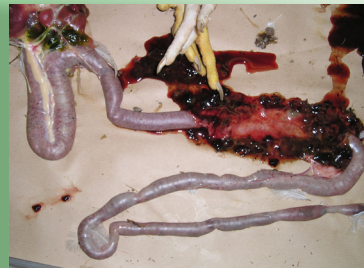1. Coccidiosis

***Eimeria necatrix* :**

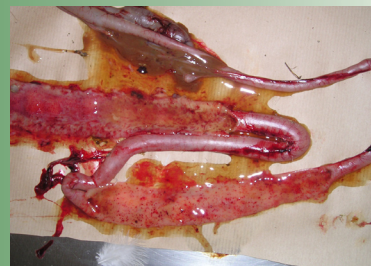
Intestine is distended twice its diameter, bloody areas are clearly seen without opening the intestine.



Partially clotted blood in the small intestine.

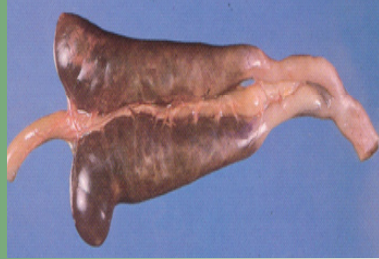

Intestine contains mucous, fresh blood and its membrane is widely covered with red tiny spots.

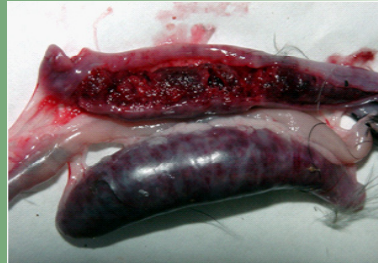

Eimeria tenella :

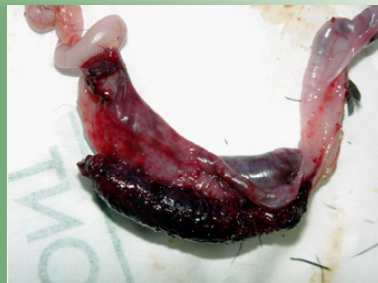Caeca distended with blood



Large quantity of blood present in the caecal, the caecal walls are thickened.

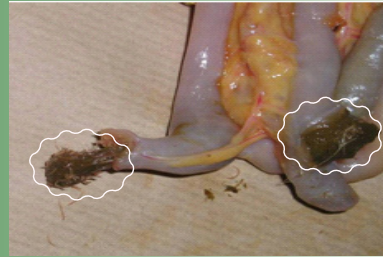

Tiny red spots scattered on caecal wall and bloody content.



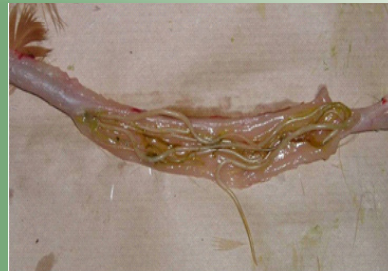2. Heterakis

Small white worms found in the tip or blind ends of the caeca (female : 10-15 mm long ; male 7-13 mm long)



3. Ascarides

Ascarid worms (round worms) in the large intestine



Picture Book of Infectious Poultry Diseases

March 2010



FAO ECTAD
P.O Box 80598
Gaborone, Botswana
Tel: +267 395 3100, Fax: +267 395 3104
www.fao-ectad-gaborone.org